

# Temporary Anchorage Device to Correct a Class III Surgical Case

By Samuel Lee, DDS, Grace Kang-Lee, DDS & Kevin La, DDS

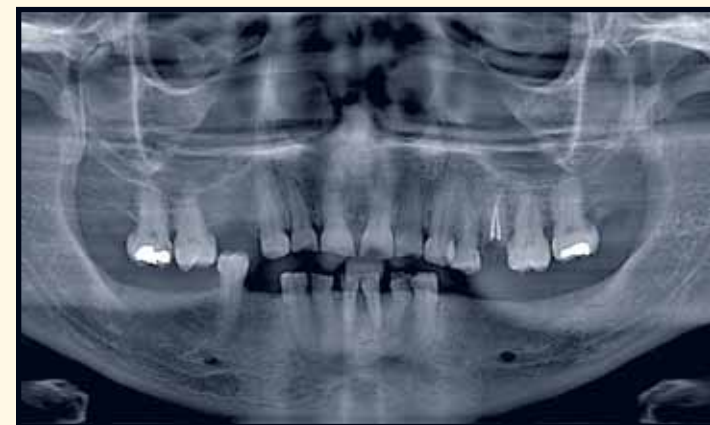

Figure 1: Preoperative panoramic radiograph shows extrusion of upper molars and lower premolar. Anterior spacing and abnormal enamel damage are due to the occlusal trauma.

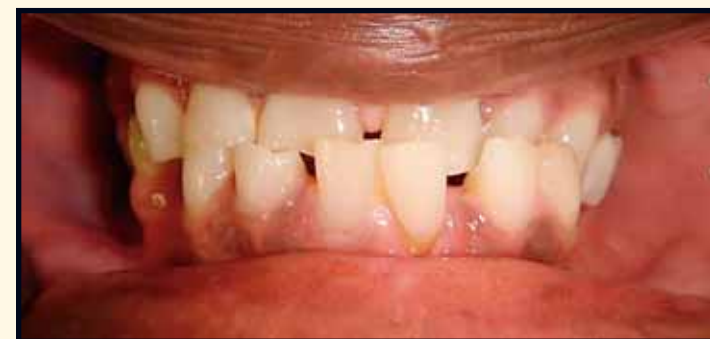

Figure 2A: Frontal intraoral picture showing anterior spacing, unusual wear of the incisor, and a periodontal defect due to occlusal trauma.

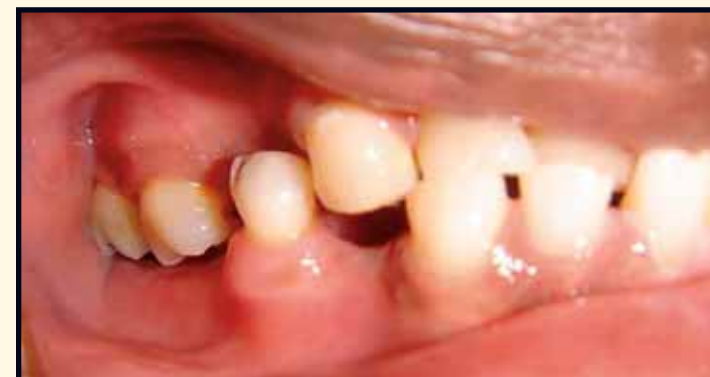

Figure 2B: Right lateral intraoral picture shows extrusion of upper molars and #29. In addition to extrusion, a crossbite relationship is observed on the posterior (lower ridge is touching buccal cusp of upper instead of lingual cusp).

In the winter 2008 edition of this journal, we described how to surgically place temporary anchorage devices (TAD, aka ortho implants, mini implants, micro implants). In this article and in the following edition, we will introduce individual cases that involve TAD's and their mechanics.

A 40 year old African American patient was referred to our office from a general dentist for dental implants. The patient had class III skeletal and dental relationships. We suggested orthodontic treatment to correct the skeletal and dental discrepancies before restoring the edentulous spaces with dental implants. Figure 1, 2, and 3 show preoperative panoramic, intraoral pictures and lateral ceph indicating the clinical challenge of the class III skeletal and dental relationship.

The lateral ceph showed dental and skeletal class III relationships. The Wits was -4mm, ANB was 0 degrees, SNA was 92 degrees and the SNB was 92 degrees (bimax protrusion). The reversed occlusal plane, deep bite tendency showing GoGn of 27 degrees, and flared out lower incisors showing lower incisor to NB at 12mm were also present. First, we decided to place lower implants (biohorizons 4.0X10mm and novelbiocare 4.2X10mm) slightly distal in order to use them as anchorage to retract the lower anteriors and premolars1 (figure 4). Then, after the lower implants integrated with bone, we planned to open up the bite using lower permanent implants, and protract the upper incisors and intrude the upper molars with TADs3. The patient received a 2nd opinion by another orthodon-

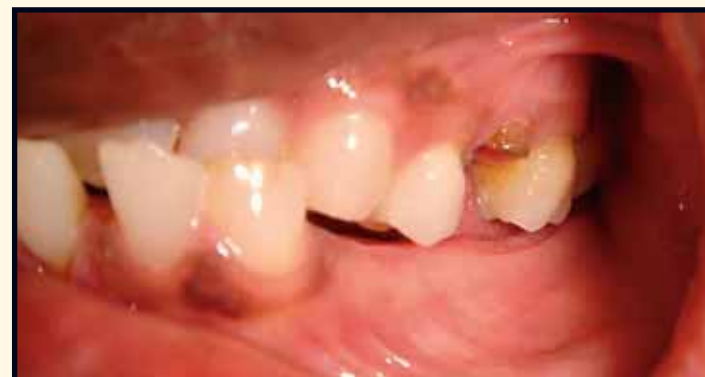

Figure 2C: Left lateral intraoral picture shows extrusion of upper molars. In addition to extrusion, crossbite relationship is observed on posterior (lower ridge is touching buccal cusp of upper instead of lingual cusp).

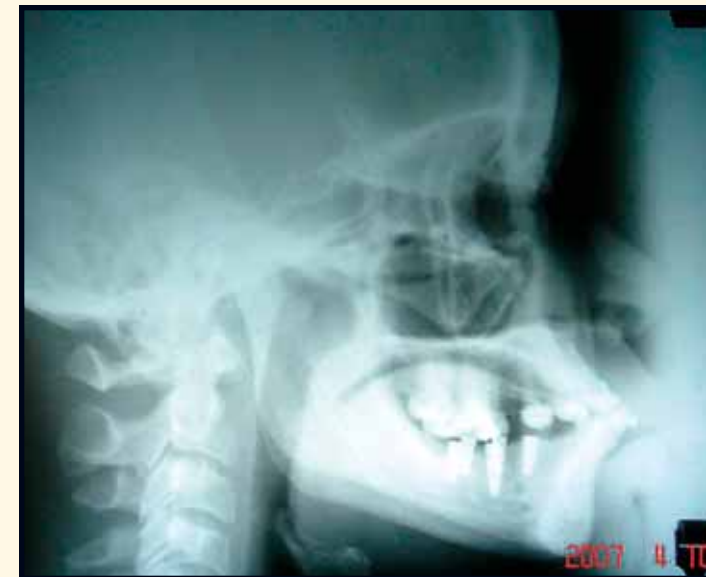

Figure 3A: Lateral ceph before orthodontics




Figure 3B: Lateral ceph tracing

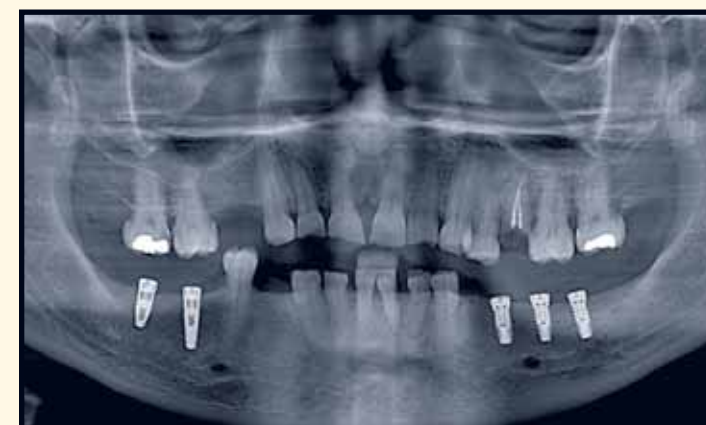

Figure 4:

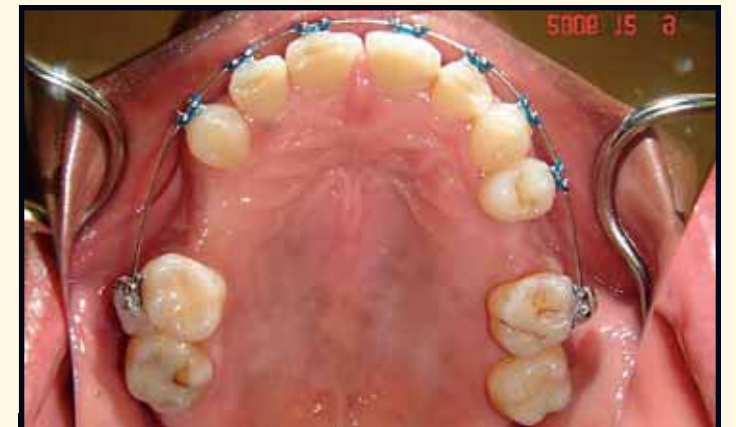

Figure 5A & 5B: Initial leveling and aligning to correct flared out incisors while waiting for the implants to integrate.

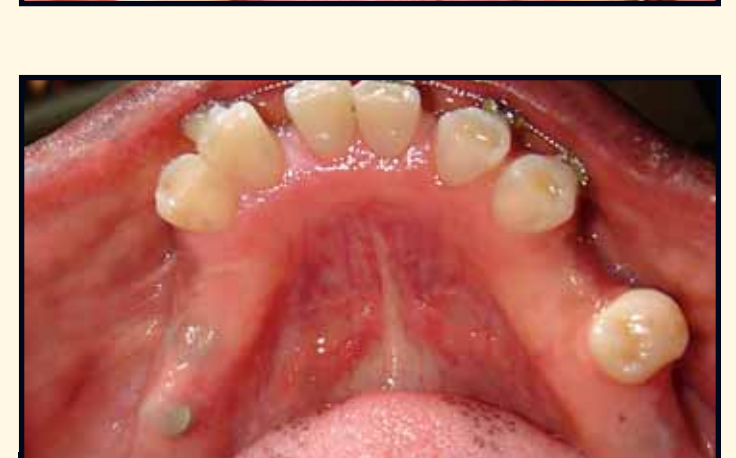
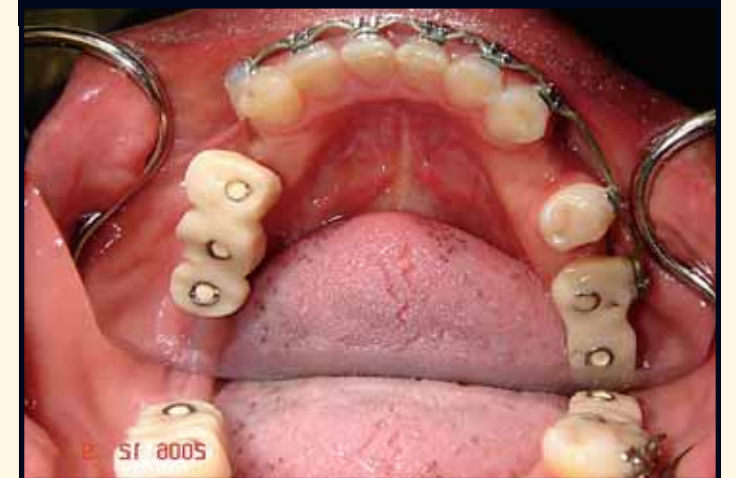
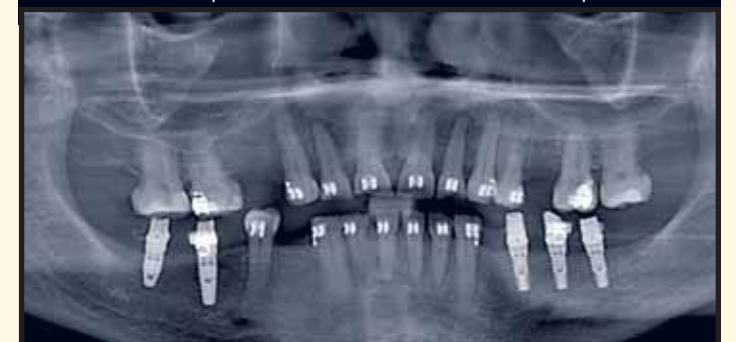Figure 5C & 5D: Lower implants are placed slightly distal to retract the lower incisors and premolars to lessen the class III dental problem.



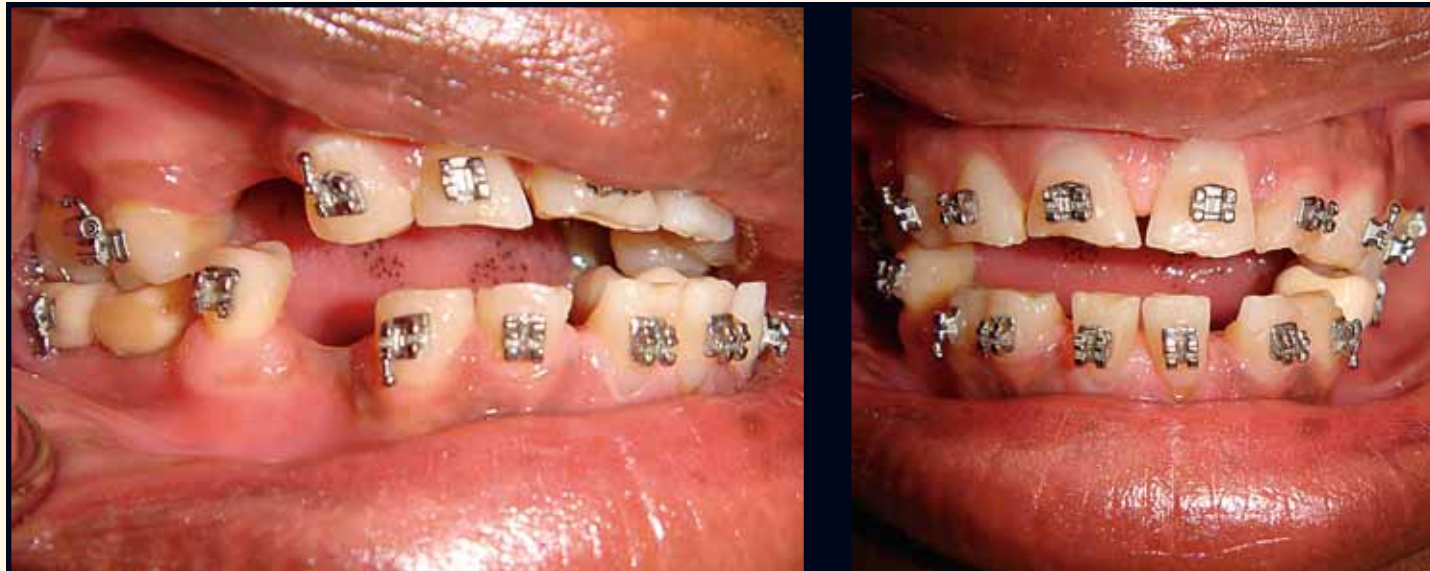

Figure 6A & 6B: After 2nd stage lower implant surgery. 8mm anterior openbite and crossbite due to extrusion of upper molars and skeletal class III relationship.

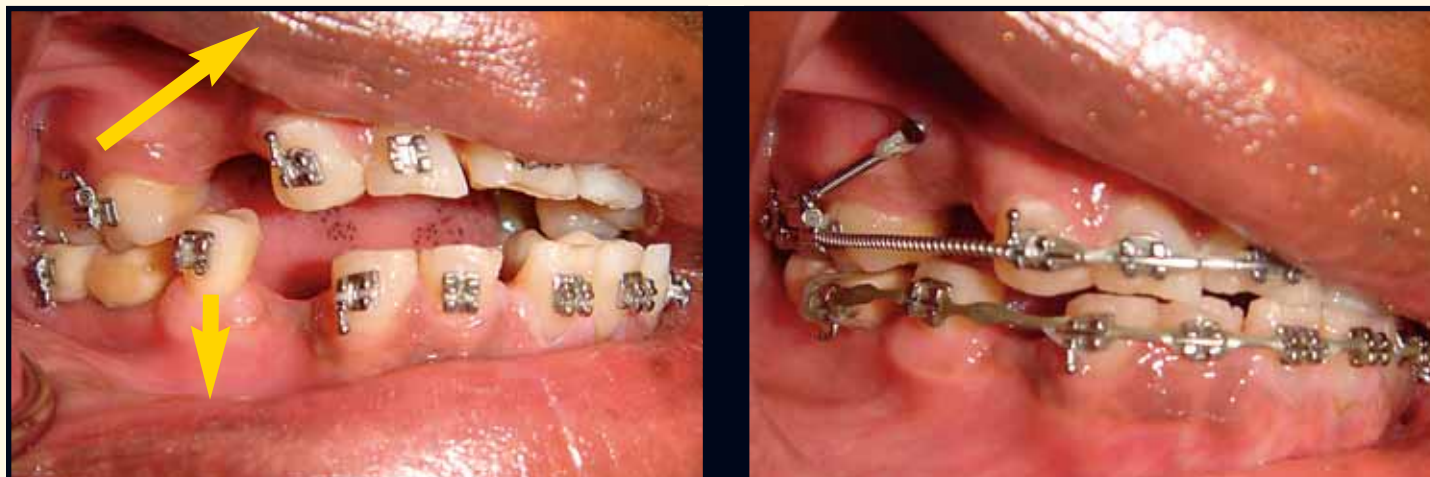

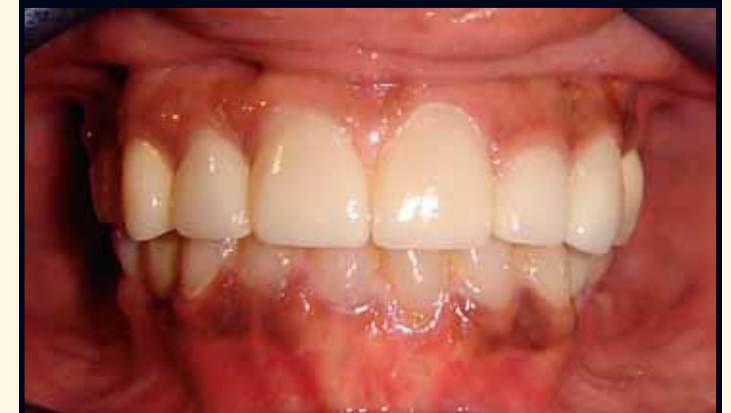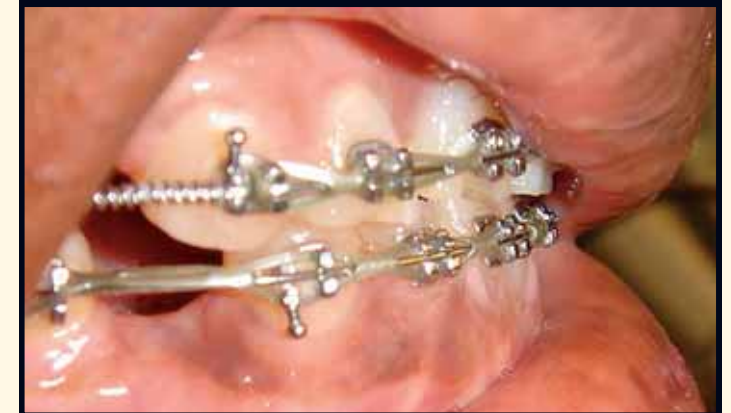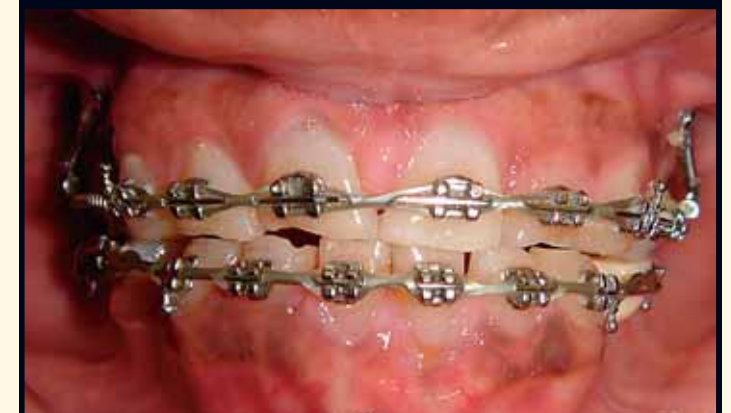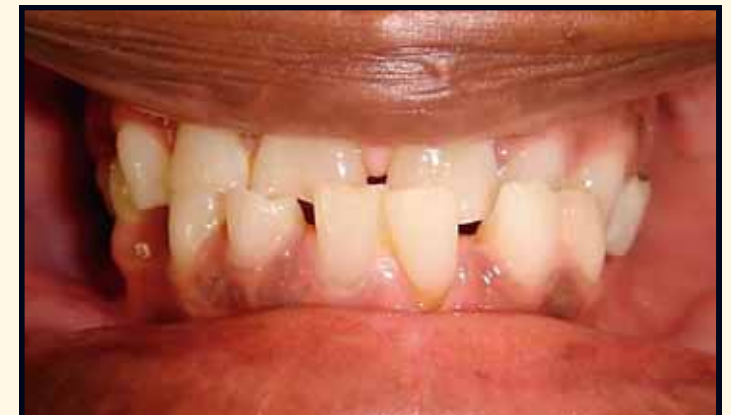Figure 7A & 7B: The TAD was placed in the area of #5 and #12 at the level above the mucogingival junction (in mucosa) to intrude the upper molars and protract the maxilla.

tist/oral surgeon. They recommended the extraction of healthy upper molars due to severe extrusion and Le Fort Surgery to bring the maxilla forward. In this article, we will show how two small screws (1.6X10mm TAD, Ortho Organizer, Calsbad, CA) preserved the healthy 4 maxillary molars by intrusion and protracted the premaxilla saving the patient from having Le Fort Surgery.

The second stage lower implant surgery was performed 6 months after the first stage surgery. Due to a lack of keratinized tissue on the buccal flap, we decided to do an apically positioned flap to gain keratinized tissue. Next a temporary crown was made with Jet acrylic and bonded to the molar brackets. An amalgam prep design was performed on the buccal of the acrylic temporary as a way of providing mechanical retention before bonding a bracket on. Powerchain was used to retract the lower incisors and intrude tooth #29 using lower permanent implant as anchorage.<sup>1</sup> (Figure 7A)

However, the real challenge was dealing with an 8mm open bite after restoring lower posterior teeth. Extrusion of

an incisor was ruled out, because the patient's upper incisor was at the correct vertical position. Extrusion of an upper incisor would lead to a gummy smile after the treatment. However, the root surface of her extruded upper molars is far greater than any other teeth in her mouth which suggests that other teeth cannot be used as anchorage to intrude upper molars. She did not want to have any extraoral devices such as headgear due to its appearance. A temporary anchorage device was the only solution that we could think of. In the maxilla, the interradiular space is very limited and cortical bone is not as dense as the mandible. Therefore, we have used it in an edentulous area (#5 and #12 are missing) and angulated the TAD in a diagonal direction apically to engage more bone (we used 1.6X10mm ortho organizer, Anchor Pro, Calsbad, CA).<sup>3</sup> However, we needed to go through the archwire sequence until we filled up our 0.022 bracket slot with 0.018X0.025 stainless steel wire before engaging the TAD to the upper archwire. A very stiff wire was necessary in order to prevent buccal tipping of molars while intrusion with the TAD.<sup>4</sup> Protraction of the



Figures 8A, B, C & D: Comparison of pre ortho, post ortho, and post restoration. Notice we treated the class III collapsed crossbite to a class I overjet.

## Case Study

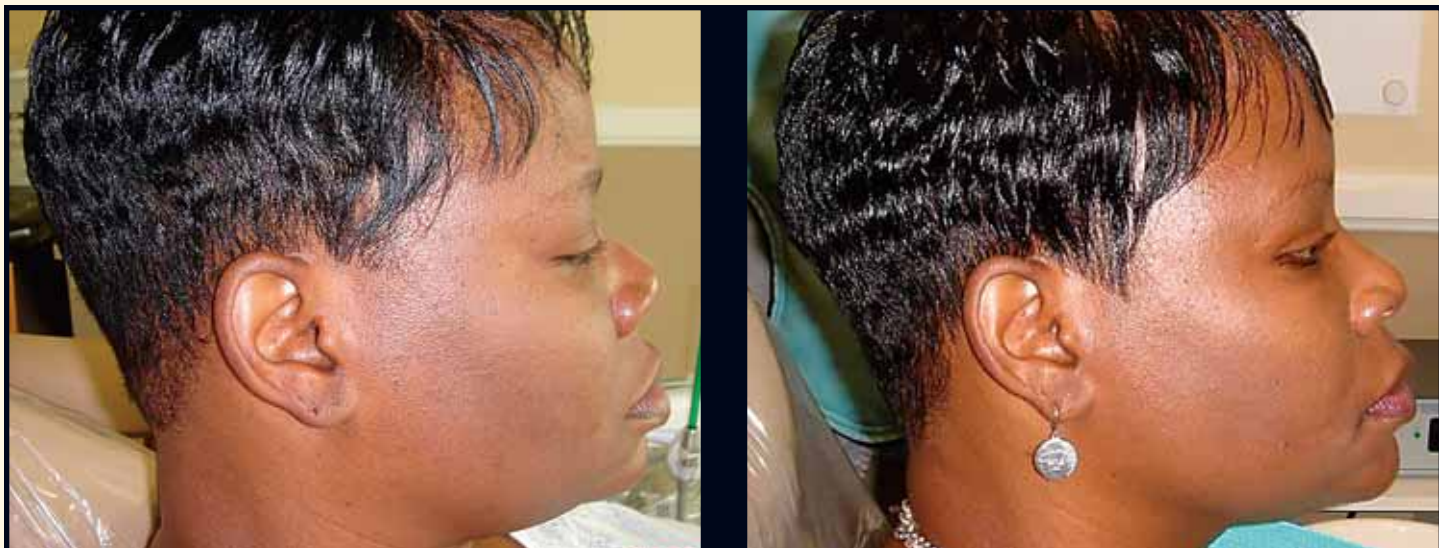

Figure 9A and 9B. Comparison of pre-op and post-op lateral extraoral picture. Notice advancement of the maxilla.

maxilla and intrusion of the upper molars was intended, so the TAD was placed in the area of #5 and #12 at the level above the mucogingival junction (in mucosa), see figure 7a and 7b. As we described in the previous edition of this journal, a TAD placed in mucosa causes irritation. Therefore, the TAD should be placed in keratinized tissue if possible.<sup>4</sup> However, in this case to intrude molars, we needed to place the TAD higher than the center of resistance of the upper molars.<sup>2</sup> A closed coil spring was used to intrude and bring the molars forward. Open coil was used in the upper premolar area to protract the premaxilla to obtain a class I overjet. (Figure 7A and 7B)

Total orthodontic treatment took 15 months. Leveling and aligning took 8 months, and antero-posterior correction and vertical correction (intrusion of upper molars) took 7 months. Absolute anchorage allows movement of multiple teeth, this may shorten treatment time as much as 3-6 months in most

cases.<sup>3</sup> After orthodontic and implant treatment from our office, she went back to her general dentist to have veneers and crowns placed as seen in figure 8D. The patient did not return with her post-op cephalogram, but her lateral facial photos show improved vertical dimension, protraction of the maxilla, straighter facial profile, and a better self esteem.

The use of TADs helped to achieve absolute intraoral anchorage, without relying on patient compliance. Without TADs, this case would require extraction of four healthy upper molars, osteoplasty and four more dental implants. Alternatively, it would require multiple Le Fort Surgeries to intrude and protract the maxilla. TADs offer definite economical advantage to the patient, and save the patient from multiple surgical trauma.

Dr. Lee is offering his one-day, hands-on seminar on TADs, on June 5 and October 25, 2008. Please contact or call 760.753.8628 for more information.

## Reference:

1. Block MS, Hoffman DR. A new device of absolute anchorage for orthodontics. *Am J Orthod Dentofacial Orthop* 1995;107:251-258
2. Bae SM, Park HS, Kyung HM, Kwon OW, Sung JH. Clinical application of micro-implant anchorage. *J Clin Orthod* 2002;36:298-302
3. Park HS, Bae SM, Kyung HM, Sung JH. Microimplant anchorage for treatment of skeletal class I bialveolar protrusion. *J Clin Ortho* 2001;35:417-422
4. Bae SM, Kyung HM. Clinical application of microimplant anchorage (MIA) in orthodontics: Anatomic consideration and surgical procedures. *Korean J Clinical Orthodontics* 2002;1:16-29

## Dr. Samuel Lee

Samuel Lee, DDS (middle), is a UCLA graduate in both Dentistry and Microbiology. He is in a group practice in Buena Park, CA, with his wife Grace Kang-Lee, DDS (Left), who is also a UCLA graduate in Dentistry and Psychology. His partner Dr Kevin La (right), is also a graduate of the UCLA Dental School. Dr.

Lee lectures nationally about dental implants and orthodontics using TAD. He is the 2007 American Orthodontic Society's Annual Meeting Best Table Clinic Award Recipient, the 2007 American Academy of Implant Dentistry's Annual Meeting Best Table Clinic Award Recipient, and also the 2008 International Congress of Oral Implantology's Best Table Clinic Award. He is very creative holding patents on several sinus lift instruments, and provides amazing comprehensive dental treatment to his patients. Please visit [www.firstchoicedentalgroup.com/seminars](http://www.firstchoicedentalgroup.com/seminars) for upcoming educational events. Dr. Samuel Lee, DDS, First Choice Dental Group, 7841 Commonwealth Ave, Buena Park, CA 90621, Tel 714 739 7173, Fax 714 739 7174, E mail: [samleedds@yahoo.com](mailto:samleedds@yahoo.com).





Free Call Aust: 1800 645 813  
Free Call NZ: 0800 440 883  
[www.OrthoOrganizers.com.au](http://www.OrthoOrganizers.com.au)